

Lorna Barlongo-Sitoy M.D., FPCOM, RMT, AMT

Fellow Phil. College of Occupational Medicine

Associate Phil. Academy of Family Physician

Hospital Accreditation: VGMH, NGH, SVGH, MM

HMO Accreditation: Intellicare, Avega, Medicaid, Life and Health
Cocolife, Lacson and Lacson, Philcare, Kieser

VICENTE GULLAS MEMORIAL HOSPITAL	SIToy MEDICAL CLINIC AND PHARMACY
RM. K	Blk 10 lot 18 Deca Homes 3 Basak LLC
MWF	MWF 3:00 - 5:00 PM
11:00 - 12:00 NN	SAT 8:00 - 5:00 PM
0925-501-83-69	09173180561

MEDICAL CERTIFICATE

To whom This may concern,

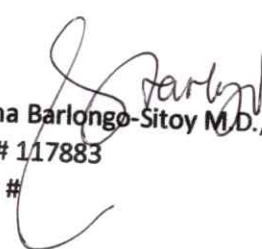
This is to certify that Frankie, Mary Ann Lim was
Seen and examined on 5/11/18 with a complaint
~~of no subjective complaint.~~
① Physical examination
Impression Diagnosis:
came in w/ CXR Result ①

PMH:
- Acute Gastritis
- STP
- Benign Thyroid

Recommendation:

> FIT TO ANY TYPE OF ACTIVITY

This certificate is issued for whatever purpose it would serve.


Lorna Barlongo-Sitoy M.D., FPCOM
Lic.# 117883
PTR #



Name : AMANTE, MARY ANN LIM

Age : 29

Physician :

Gender : F

Address : NASIPIT, TALAMBAN, CEBU CITY, CEBU, PH, 6000

Result Date: 1/16/2018 10:14:00AM

XRAY REPORT

CHEST X-RAY PA

REPORT :

PA view of the chest reveals the lung fields are clear.
Heart is normal in size, shape and configuration.
Mediastinal structures are midline in location.
Both hemidiaphragms and lateral recesses are sharp and distinct.
Visualized osseous structures showed no significant abnormality.

IMPRESSION : NORMAL CHEST.

NOTE: This report is based on radiographic study & should be correlated w/ other clinical & laboratory findings.

RAFAEL C. MEDECIELO JR., XRT

Technologist

JEE D. DOMAEL, M.D, DPBR

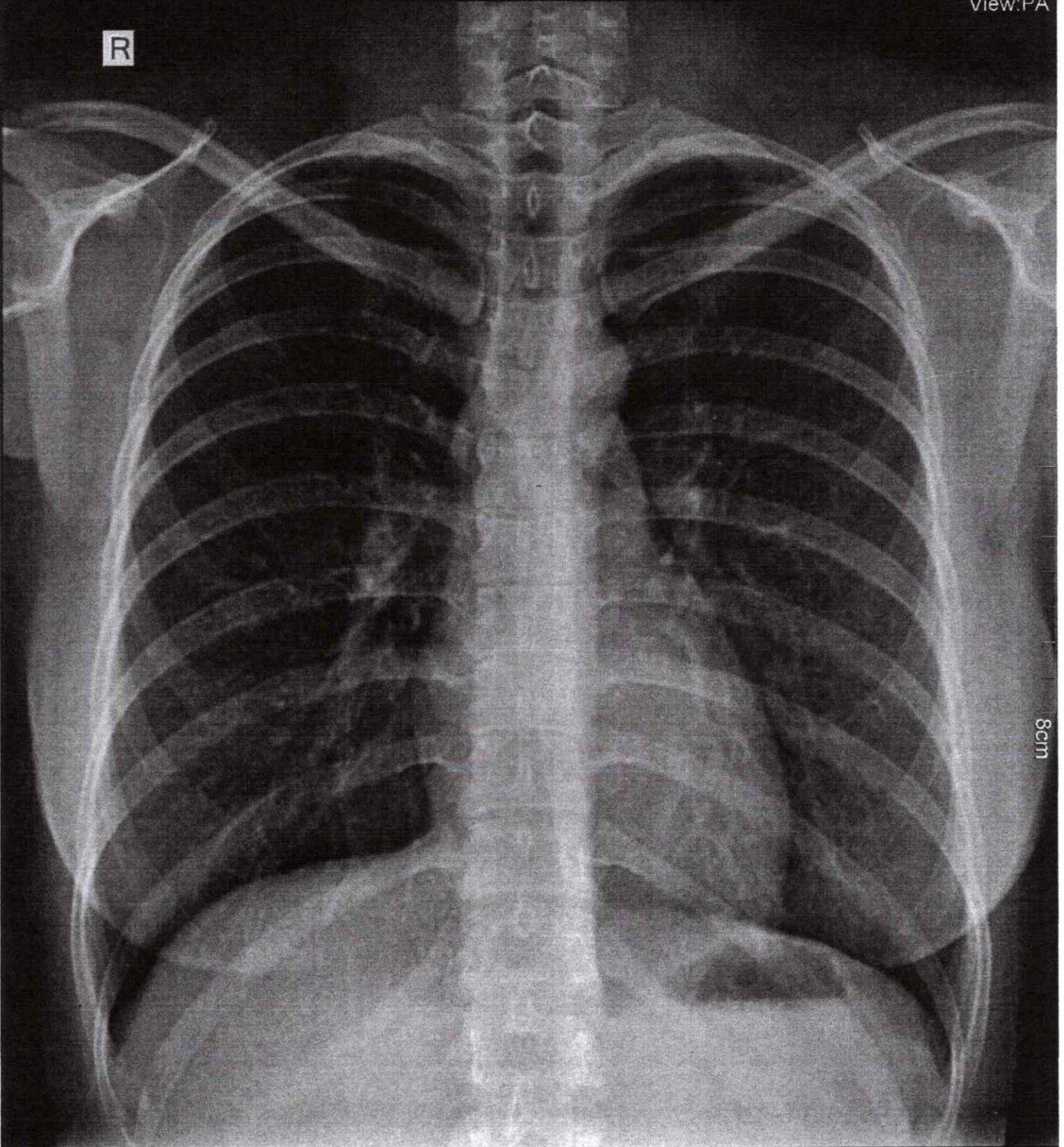
RADIOLOGIST

Date Printed : 1/16/2018 10:14:15AM

Name: AMANTE, MARY ANN LIM.,
Age: 29Y
Sex: Female

PID: 201000246180
DATE ACQ: 2018.01.15
PROC: CHEST
View: PA

R



8cm

LH Prime Medical Clinic Mandaue

4cm

EI: 1362
TECH: tech

NOT FOR DIAGNOSIS - INTENT COPY ONLY