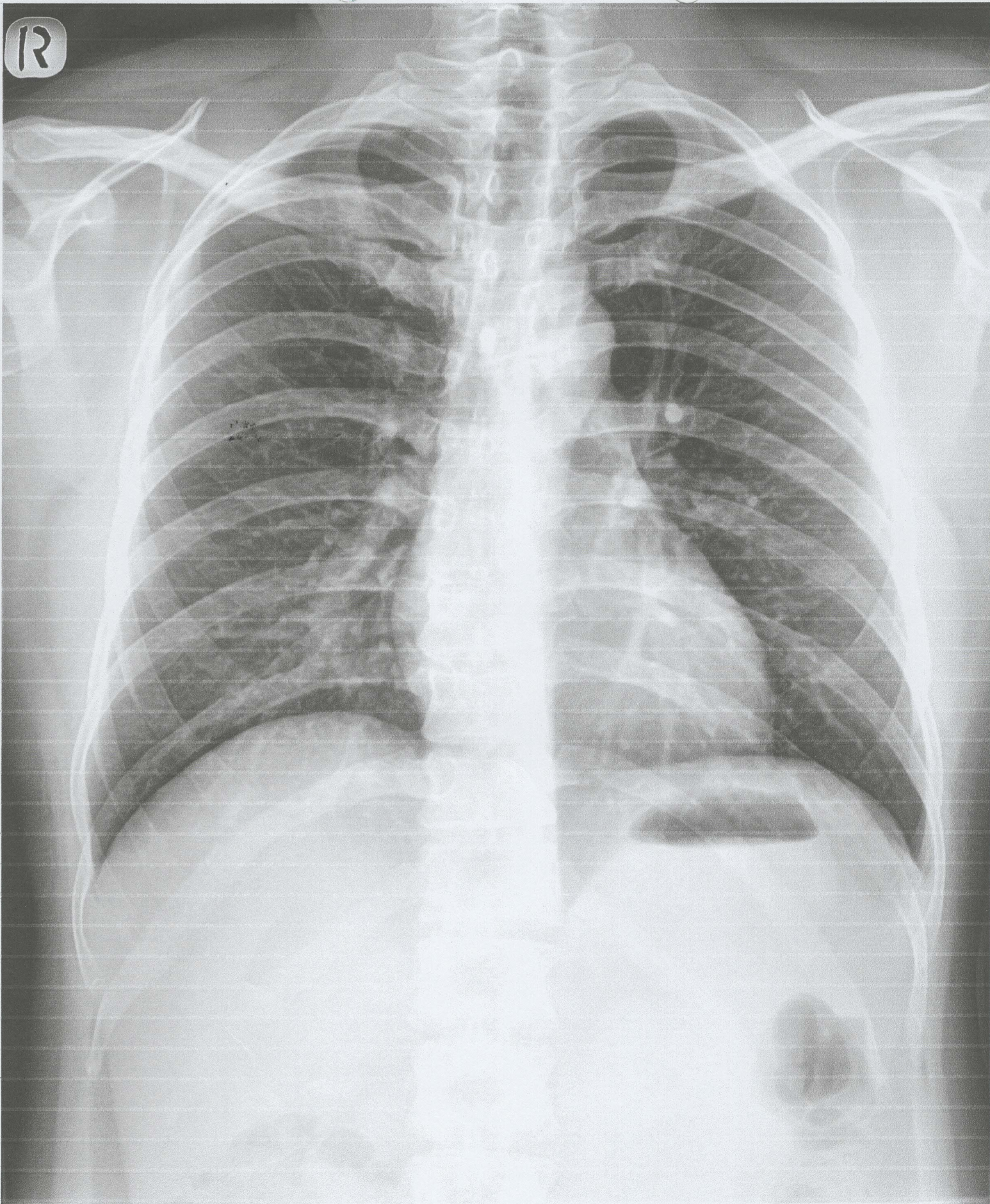


R



Patient ID: 19-12351 G ANGLE ENTERTAINMENT  
Patient Name: PINO, LEMUEL  
Study Date: 07/15/2019